

Keratoameloblastoma A Rare Entity: A Case Report

SANGEETA J. PALASKAR¹, RASIKA B. PAWAR², DEEPAKKUMAR D. NAGPAL³, SWATI S. PATIL⁴, PARGATSINGH T. KATHURIYA⁵

ABSTRACT

Ameloblastoma is the second most common odontogenic tumour of oral cavity; which has several different histological variants such as follicular, plexiform, acanthomatous, granular cell, desmoplastic, basal cell, clear cell, hemangiomas, mucous cell differentiation and keratoameloblastoma. It is common in posterior mandible and has high male predilection in the ratio of 3:1. This report presents a case of keratoameloblastoma in 65-year-old female patient in the anterior mandible region with literature review on clinical features, histopathological findings, radiological appearance and treatment options.

Keywords: Ameloblastoma, Acanthomatous, Histological variants, Mandible

CASE REPORT

A 65-year-old female presented with a complaint of pain and swelling in the anterior mandible since 2 to 3 months. Patient's family history and medical history were not contributory. On examination, a single swelling was seen in mandibular labial vestibule extending from left to right canine region, measuring around 7 X 3 cm in its greatest diameter, covered with smooth surface and pale pink in colour [Table/Fig-1]. Teeth in the area of lesion were missing and lesion was obliterating the labial vestibule making cortical expansion obvious. Palpation revealed a firm, non tender swelling with regular borders. Patient underwent fine needle aspiration cytology, which was suggestive of giant cell lesion. Hence provisional diagnosis was made as central giant cell granuloma. Radiological examination revealed perforation of labial cortical plate in lateral view. Cone beam computed tomography scan revealed erosion of mandible suggesting a neoplastic process [Table/Fig-2]. Taking into consideration the cytological and radiological findings, the lesion was surgically excised and the tissue was sent for histopathological examination.

Microscopic examination of excised specimen revealed follicles and plexiform patterns lined by ameloblast like cells with extensive squamous metaplasia and keratin formation in the center [Table/Fig-3]. Connective tissue stroma displayed lamellated stacks of keratin pearls. Dense chronic inflammatory cell infiltrate was found around the large keratin pearls in the connective tissue stroma. Multinucleated reactive giant cells were also found [Table/Fig-4]. These features suggested the diagnosis of keratoameloblastoma. On follow-up after 4 months, patient reported with the same lesion on the same site, keep in mind the lesion has recurred, the surgeons then performed block resection of the anterior mandible. Later patient lost the follow-up.

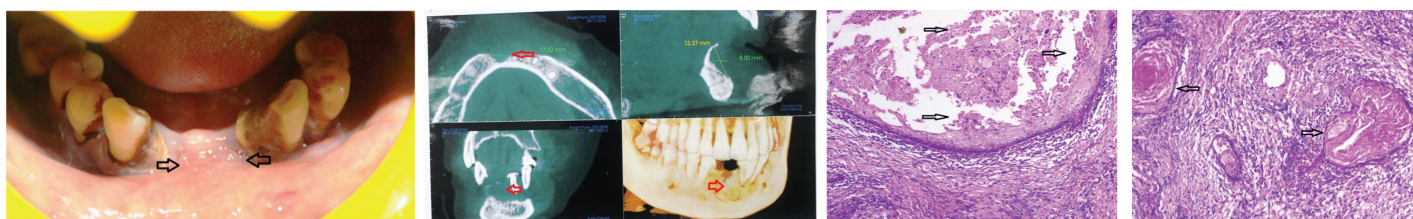
DISCUSSION

Keratoameloblastoma is an extremely rare variant of ameloblastoma [1] with only 17 cases reported in the literature till October 2014. In 1992, the World Health Organization (WHO) defined KA as an ameloblastoma with extensive keratinization, although the recent WHO classification for odontogenic Tumour has not mentioned this term [2,3]. WHO accepted this lesion in histologic spectrum of acanthomatous ameloblastoma due to focal keratinization [4]. According to Norval et al., KA is a variant of acanthomatous ameloblastoma [2,5]. The reported 17 cases of KA are summarized in [Table/Fig-5].

It has more male predilection than female in the ratio of 3:1. The present case was diagnosed in a female patient. KA is most commonly diagnosed in the age groups ranging from 3rd to 7th decade of life with the mean age of occurrence is 43.8 years [2]. Posterior mandible is more commonly involved followed by maxilla, 13 out of 17 reported cases showed involvement of the mandible where as four cases were present in maxilla [1,3]. In this case the lesion was present anteriorly in the mid -line of mandible.

Radiographic appearance varied from unilocular to multilocular radiolucency with central calcifications seen in two case reports [1-3]. In the present case, unilocular radiolucency was present with erosion of bony margin and perforation of labial cortical plate.

Whitt et al., [2] summarized the histologic features of KA into 4 subtypes as- (1) Papilliferous histology - in which the odontogenic epithelium is in papillary projections into the cystic spaces, (2) Simple type - in which histology represents epithelial follicles filled with parakeratin or orthokeratin and lined by ameloblast like cells with reversal of polarity; (3) Simple with Keratocystic Odontogenic Tumour (KCOT) like features- showed similar features of simple type in addition it contains features of conventional odontogenic



[Table/Fig-1]: Swelling in the anterior mandible causing obliteration of labial vestibule

[Table/Fig-2]: Cone beam computed tomography revealed unilocular radiolucent lesion causing erosion of bone

[Table/Fig-3]: Photomicrograph showing ameloblastic follicles with squamous metaplasia in the center (10X)

[Table/Fig-4]: Photomicrograph showing extensive areas of keratin deposition surrounded by chronic inflammatory cells in the connective tissue stroma (10X)

Sr. No.	Author	Age/ Gender	Clinical features	Radiographic features	Histopathologic features	Treatment	Follow ups
1	Pindborg [6]	57/F	Right mandibular body and ramus	Multilocular radiolucency	Papilliferous histology	Unknown	unknown
2	Altini et al., [7]	28 /M	Anterior maxilla	Multilocular radiolucency	Simple histology	Wide local excision	unknown
3	Altini et al., [8]	76/ M	Right mandible	Multilocular radiolucency	Papilliferous histology	Hemi mandibulectomy	No evidence till 12 months
4	Siar et al., [9]	30/ M	Anterior mandible	Multilocular radiolucency	Simple histology with OKC like features	Resection	unknown
5	Siar et al., [9]	35/M	Left mandible	Unknown	Simple histology with OKC like features	Hemi mandibulectomy	unknown
6	Siar et al., [9]	35 /F	Right maxilla	Ground glass with indistinct borders	Simple histology with OKC like features	Unknown	unknown
7	Siar et al., [9]	39/ F	Left anterior mandible	Unilocular radiolucency	Simple histology with OKC like features	Enucleation	unknown
8	Norval et al., [5]	26/ F	Right mandible, erosion of bone	Lobulated radiolucency	Complex histology	Segmental resection	unknown
9	Saidal Naief et al., [10]	26 /M	Right posterior maxilla	Well defined unilocular radiolucency	Simple histology with OKC like features	Curettage and partial maxillectomy	Recurrence after curettege with in 6 month. Unknown after maxillectomy
10	Kaku T [11]	35 /M	Right body of mandible	Unilocular radiolucency between roots	Simple histology	Unknown	Unknown
11	Takeda et al., [12]	76 /M	Left body of mandible	Multilocular radiolucency	Complex histology	Resection	Unknown
12	Collini P et al., [13]	62 /M	Right ramus and condyle of mandible	Irregular radiolucency with calcification	Papilliferous histology	Hemi mandilectomy	Two local recurrences at 36 and 38 months
13	Whitt et al., [2]	45/M	Anterior maxilla	Unilocular radiolucency with calcification	Complex histology	Currettage	No evidence at 10 month
14	Adeyemi et al., [1]	38/ M	Right posterior mandible	Multilocular radiolucency	Stromal parakeratin deposition with focal cystic change in epithelial islands. Areas of myxoid change	Resection of mandible	unknown
15	Mohanty N et al., [14]	46 /M	Right posterior mandible	Multilocular radiolucency	Papilliferous histology	Unkown	Unkown
16	Ketabi MA et al., [15]	21 /F	Right anterior Mandible	Unilocular radiolucency	Complex histology	Enucleation	No recurrence upto 12 months followup
17	Raj V et al., [16]	22/F	Right Posterior Mandible	Unilocular radiolucency	Simple histology with stroma showing myxoid areas and cystic degeneration	Segmental resection	No recurrence upto 24 months followup
18	Present Case	65/ F	Anterior Mandible	Unilocular radiolucency	Complex histology except for hard tissue formation	Excision and block resection of mandible	Recurrence after excision within 4 months, Unkown after block resection of mandible

[Table/Fig-5]: Review of previously reported cases of kearatoameloblastoma with clinical, radiographic, and histologic features

keratocyst, (4) Complex histology-consists of epithelial follicles packed with parakeratin or orthokeratin, extrusion of keratin masses into connective tissue stroma in the form of pacinian like stacks with or without foreign body reaction; also there may be hard tissue formation resembling cementum and woven bone [2,3,5]. Our case showed complex histology except for hard tissue formation.

As there is overlap of histologic features between KA and solid variant of KCOT, it is important to distinguish between these two lesions. Features present in KA are- (1) stellate reticulum or its differentiation to squamous cells, granular cells or basal cells; (2) large amount of keratin pearl deposition in the connective tissue [17]. These features are absent in solid variant of KCOT.

The treatment for KA and conventional ameloblastoma or solid variant of KCOT is same i.e. block resection [18]. However, it is difficult to assess whether the biologic behavior of KA differs from other histologic types of ameloblastomas due to less no of cases reported in the literature. In the present case, the patient reported with recurrence in the same region during the follow up after four months and operated for the same. After that, patient lost the follow-up. Out of 17 cases reported in the literature, two cases had recurred. Therefore, the incidence of recurrence of

keratoameloblastoma cannot be mentioned based on scarcity of the cases reported. Although, it is a combination of two benign but aggressive lesions, the rate of recurrence and malignant potential needs to be studied [19].

CONCLUSION

KA is a rare tumour. It differs from acanthomatous ameloblastoma having keratin deposition in the connective tissue. Our case showed complex histology without any hard tissue formation which also showed clinical recurrence after four months. It is therefore mandatory to keep follow up of such cases for longer duration to know the biological behaviour of the lesion.

REFERENCES

- [1] Adeyemi BF, Adisa AO, Fasola AO1, Akang EE. Keratoameloblastoma of the mandible. *J Oral Maxillofac Pathol.* 2010;14(2):77-79.
- [2] Whitt JC, Dunlap CL, Sheets JL, Thompson ML. Keratoameloblastoma: a Tumour sui generis or a chimera? *Oral Surg Oral Med Oral Radiol Endod.* 2007;104:368-76.
- [3] JM Sisto, GG Olsen. Keratoameloblastoma: complex histologic variant of Ameloblastoma. *J Oral Maxillofac Surg.* 2012;70:860-64.
- [4] Gardner DG, Heikinheima K, Shear M, et al. World Health Organization Classification of Tumours: Pathology of Head and Neck Tumours. 1st ed. Lyon, France, IARC Press, 2005, pp. 296.

- [5] Norval EJ, Thompson IL, VanWyk CW. An unusual variant of keratoameloblastoma. *J Oral Pathol Med.* 1994;23:465.
- [6] Pindborg JJ. Pathology of the dental hard tissues. Philadelphia(PA): W. B. Saunders; 1970. pp. 381-82.
- [7] Altini M, Lurie R, Shear M. A case report of keratoameloblastoma. *Int J Oral Surg.* 1976; 5(5):245-49.
- [8] M Altini, HD Slabbert, T Johnston. Papilliferous keratoameloblastoma. *J Oral Pathol Med.* 1991;20(1):46-48.
- [9] Sair CH, Ng KH. "Combined ameloblastoma and odontogenic keratocyst" or "keratinizing ameloblastoma". *Br J Oral Maxillofac Surg.* 1993;31(3):183-86.
- [10] Said- al- Naief NA, Lumerman H, Ramer M, et al., keratoameloblastoma of maxilla. A case report and review of literature. *Oral Surg Oral Med Oral Pathol Oral Radiol Endod.* 1997; 84(6):535-39.
- [11] Kaku T. Keratoameloblastoma of the mandible. *J Oral Pathol Med.* 2000;29:350.
- [12] Takeda Y, Satoh M, Nakamura S, et al., Keratoameloblastoma with unique histological architecture: An undescribed variation of ameloblastoma. *Virchows Arch.* 2001;439:593.
- [13] Collini P, Zucchini N, Vessellhia G, et al., Papilliferous keratoameloblastoma of mandible: A papillary ameloblastic carcinoma: Report of a case with a 6 year follow-up and review of the literature. *Int J Surg Pathol.* 2002;10:149.
- [14] Mohanty N, Rastogi V, Misra SR, Mohanty S. Papilliferous keratoameloblastoma: an extremely rare case report. *Case Rep Dent.* 2013;2013:706128. doi: 10.1155/2013/706128. Epub 2013 Jun 3.
- [15] Ketabi MA, et al., Keratoameloblastoma, a very rare variant of ameloblastoma. *J Craniofac Surg.* 2013;24(6):2182-86.
- [16] Raj V, Chandra S, Bedi RS, Dwivedi R. Keratoameloblastoma: Report of a rare variant with review of literature. *Dent Res J.* 2014;11:610-14.
- [17] A Shuster, B Shlomi, V Reiser, I Kaplan. Solid keratocystic odontogenic Tumour – report of a nonaggressive case. *J Oral Maxillofac Surg.* 2012;70(4):865-70.
- [18] Marx R, Stern D: Oral and Maxillofacial Pathology. Hanover Park, IL, Quintessence Publishing, 2003. Pp. 646.
- [19] Netto R, Cortezzi W, Merly F, Fróes R, Abrahão A. Keratoameloblastoma: a rare case of recidivation of a rare lesion. *Int J Oral Maxillofac Surg.* 2013;42(10):1174.

PARTICULARS OF CONTRIBUTORS:

1. Professor and Head, Department of Oral Pathology and Microbiology, Sinhgad Dental College and Hospital, Vadagaon (bk), Pune, Maharashtra, India.
2. Postgraduate Student, Department of Oral Pathology and Microbiology, Sinhgad Dental College and Hospital, Vadagaon (bk), Pune, Maharashtra, India.
3. Reader, Department of Oral Pathology and Microbiology, Sinhgad Dental College and Hospital, Vadagaon (bk), Pune, Maharashtra, India.
4. Postgraduate Student, Department of Oral Pathology and Microbiology, Sinhgad Dental College and Hospital, Vadagaon (bk), Pune, Maharashtra, India.
5. Postgraduate Student, Department of Oral Pathology and Microbiology, Sinhgad Dental College and Hospital, Vadagaon (bk), Pune, Maharashtra, India.

NAME, ADDRESS, E-MAIL ID OF THE CORRESPONDING AUTHOR:

Dr. Rasika Pawar,
Postgraduate Student, Department of Oral Pathology and Microbiology, Sinhgad Dental College and Hospital,
Vadagaon (bk), Pune, Maharashtra-411041, India.
E-mail : rasikapawar0710@gmail.com

Date of Submission: **May 27, 2014**Date of Peer Review: **Jan 12, 2015**Date of Acceptance: **Jan 19, 2015**Date of Publishing: **Mar 01, 2015****FINANCIAL OR OTHER COMPETING INTERESTS:** None.